

Brain Tumor Panel

Panelists:

Stephen Karlovits, MD

- Allegheny General Hospital

P. Mark Li, MD, PhD

- Lehigh Valley Health Network

Tara Morrison, MD, FRCP(C)

- Fox Chase Cancer Center

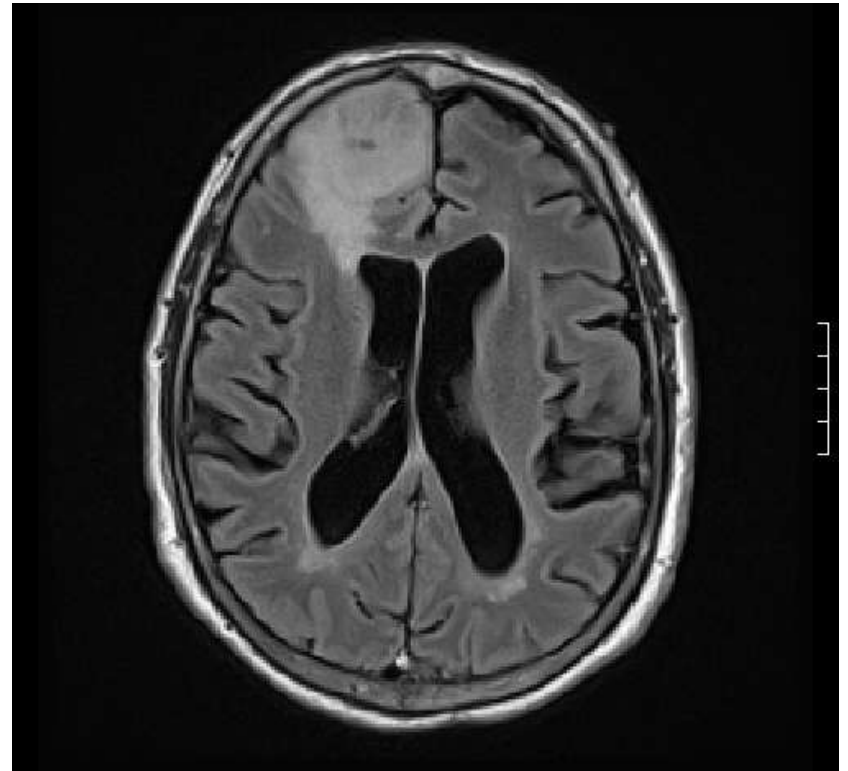
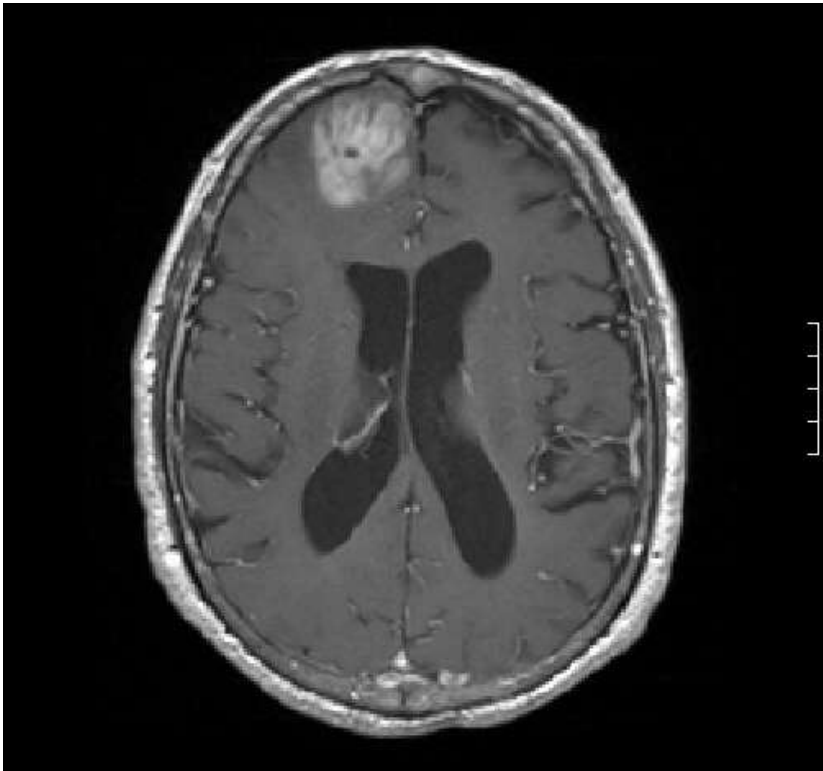
LuAnne Procyk, MSN, RN, CNRN

- Lehigh Valley Health Network

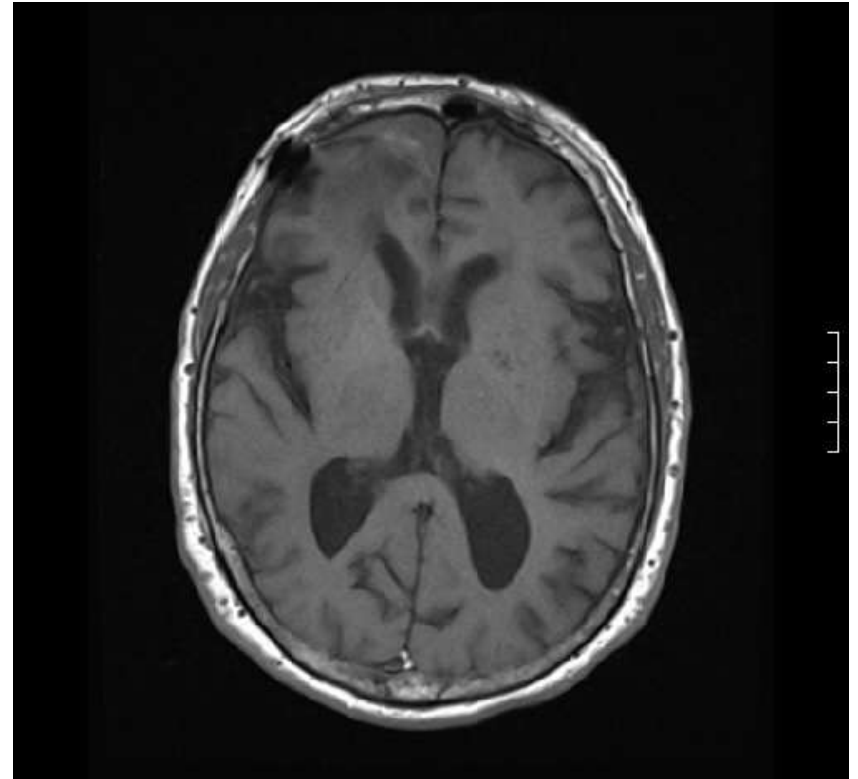
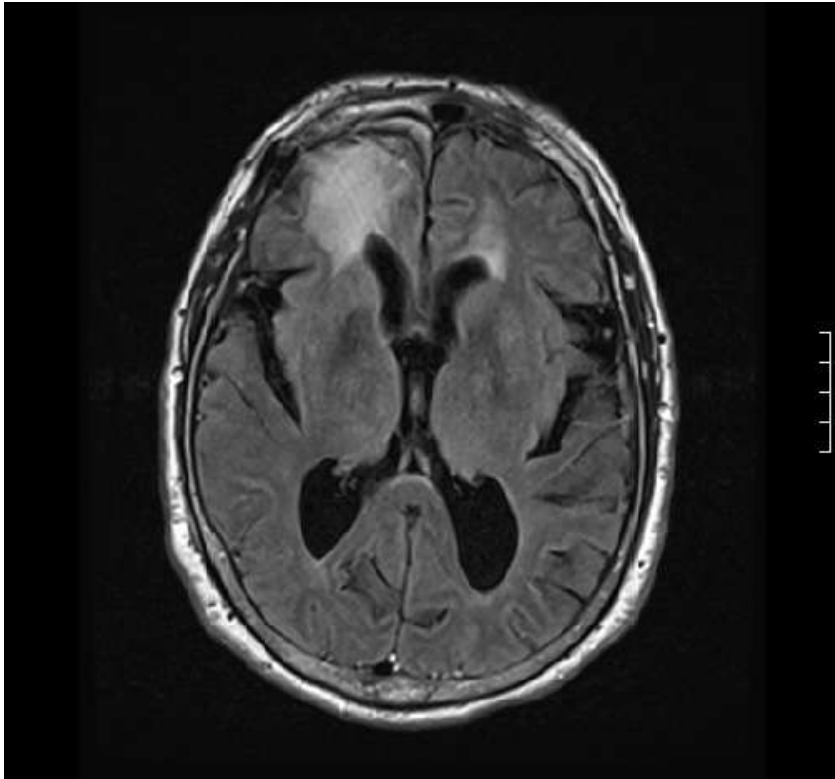
Objective: Discuss how patients with CNS malignancies would be treated with a multidisciplinary approach.

Case 6

51 year old male presented with grand mal seizures. MRI head revealed a 4cm mass in the right frontal lobe with edema.



This mass was removed at craniotomy. Histology was ganglioglioma, WHO Grade III, in association with cortical dysplasia. Outside pathology consultation confirmed the diagnosis. What do you recommend for further management?



Follow up: the patient received concurrent radiotherapy and temazolomide followed by monthly temazolomide. At 8 months he developed recurrent seizures with radiologic disease progression for which he underwent additional surgery.

