

# **Brain Tumor Panel**

## **Panelists:**

**Stephen Karlovits, MD**

**- Allegheny General Hospital**

**P. Mark Li, MD, PhD**

**- Lehigh Valley Health Network**

**Tara Morrison, MD, FRCP(C)**

**- Fox Chase Cancer Center**

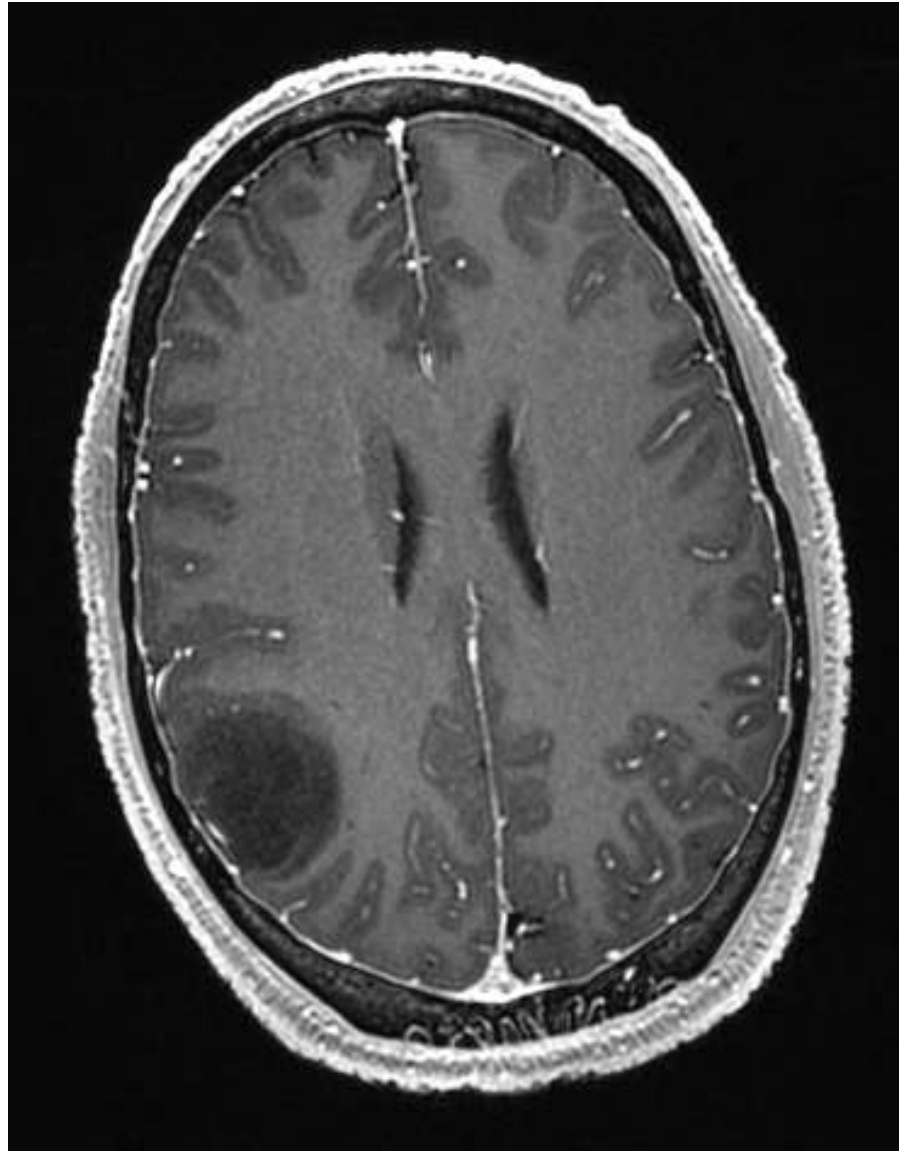
**LuAnne Procyk, MSN, RN, CNRN**

**- Lehigh Valley Health Network**

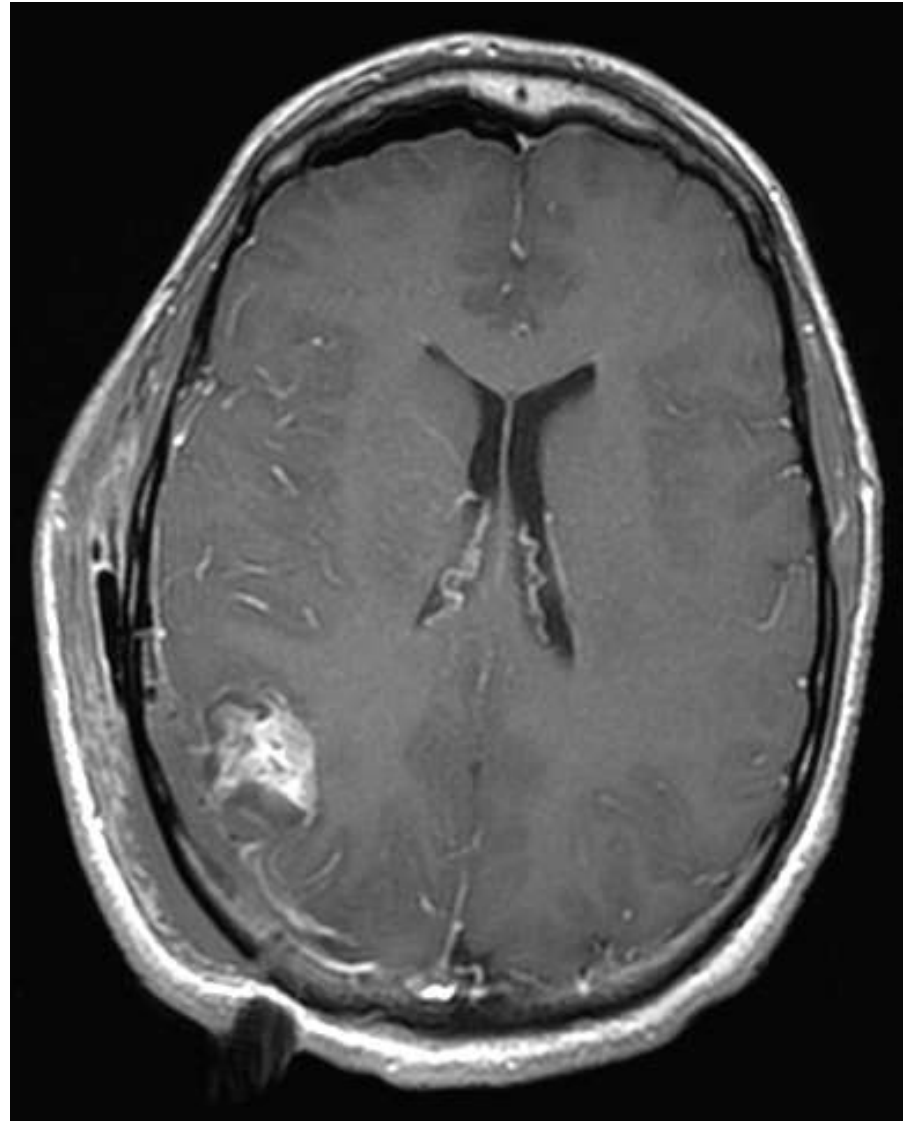
**Objective: Discuss how patients with CNS malignancies would be treated with a multidisciplinary approach.**

# Case 2

- 28 year old right handed male with new onset seizure



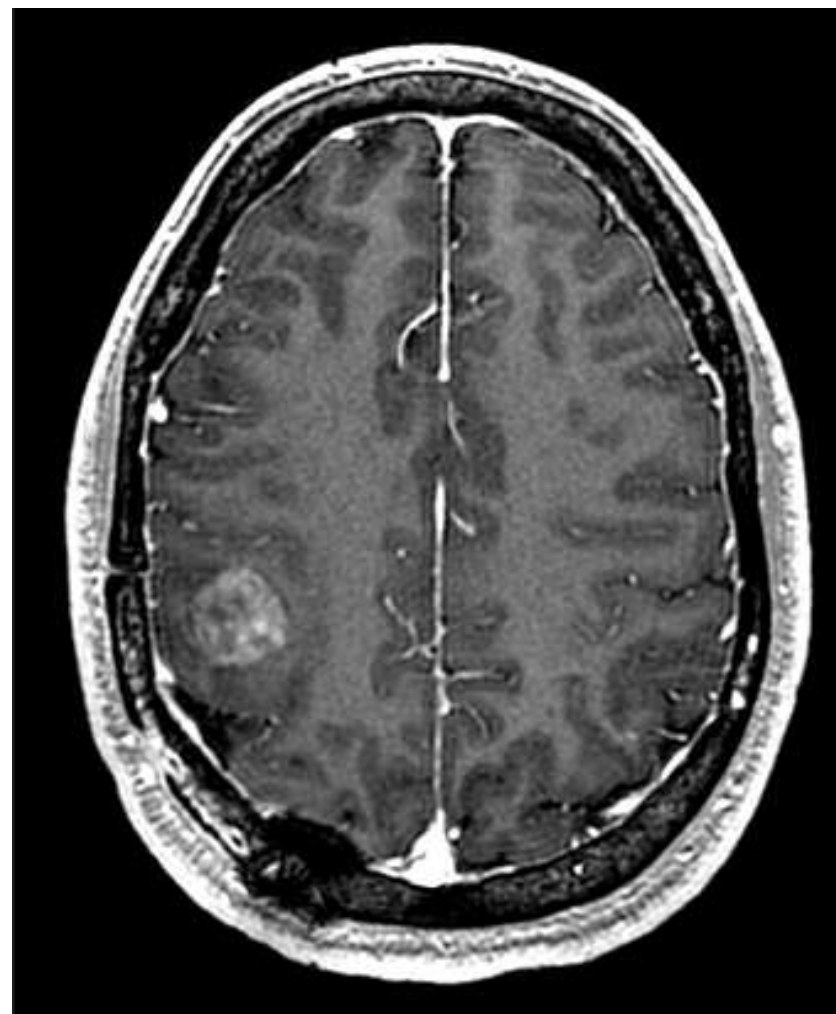- Had surgery 11/2010
- Pathology
  - Grade II oligodendroglioma
  - Low Ki-67
  - Normal copies of 1p19q
- Next steps in therapy?



# Clinical Course

- Saw a neuro-oncologist at another center who advised no adjuvant therapy needed; but close imaging surveillance warranted

- Continued to have seizures despite AED's
- Imaging (6/2012) revealed recurrence anterior to the previous tumor location
- Next step?



- Path
  - Anaplastic oligoastrocytoma grade III
    - Ki-67- 20%
- Recommendation?

